CASE REPORT

Radial Ray Syndrome with Single Umbilical Artery

Mukesh Mittal*, Pankaj Nitharwal, Abadhesh Kumar Sharma*****

ABSTRACT

3D Ultrasound antenatal examination is used for the assessment of abnormal anatomical findings. Radial ray defect can be diagnosed by using ultrasonography. Abnormal findings can be detected quickly by having the understanding of the etiology, pathophysiology and embryology. It is a rare congenital defect that may be isolated or associated with other anomalies including fanconi's syndrome and holt-oram syndrome[1]. We are reporting the case of a 28-year-old woman (G2P1L1) who presented for routine antenatal ultrasound. The patient did not have any antenatal anomaly scan. On ultrasound, gestational age of fetus was 25 weeks 3 days with short right forearm and absence of right radius with bowing of the ulna and radial deviated right hand (club hand) and associated single umbilical artery. Finding of the club hand diagnosed on 2D ultrasound was further confirmed on 3D ultrasound. Based on the finding of complete absence of radius this was diagnosed as unilateral type IV radial ray syndrome.

INTRODUCTION

Radial ray malformation refers to a spectrum of congenital anomalies that involve the radius, carpal bones or thumb. Multiple anomalies can be associated with radial ray defect. Abnormalities of any organ system, including musculoskeletal, spinal, cardiothoracic, gastrointestinal, or genitourinary can be associated with radial ray defects[2]. Radial Ray syndrome is rare malformation occurs in 1 in 30000 live births. Radial ray anomalies can be associated with a number of associations which include: Aase syndrome, Amniotic band syndrome, Cornelia de Lange syndrome (CDLS), Duane radial ray syndrome (DRRS), Fanconi anaemia, Holt-Oram syndrome, Nager syndrome, Omphalocele-radial ray (ORR) complex, Rothmund-Thomson syndrome (RTS), TAR syndrome, Trisomy 18 (Edwards syndrome), VACTERL association and Teratogen exposure in utero valproic acid and thalidomide.

On the extent of severity Radial ray syndrome can be classified into four main subtypes[3]:

1. Type I: Radius is slightly (>2 mm) short and the hand bends sideways at the wrist (often associated with a hypoplastic thumb); proximal radius is usually unaffected.
2. Type II: Radius bone is very short and the ulna curves sideways and supports the wrist poorly.
3. Type III: Partial absence of radius bone.
4. Type IV: Complete absence of radius bone.

CASE PRESENTATION

A 28-year-old woman of Indian origin, G2P1L1, presented to an obstetrical outpatient department for routine antenatal check-up. The patient's gestational history was unremarkable, with no significant past medical or surgical events. There was no significant history of drug intake. Her menstrual cycles were regular. No previous antenatal anomaly scan was done. Patient was referred to radiology department for antenatal scan. On ultrasound, gestational age of fetus was 25 weeks 3 days with short right forearm and absence of right radius with bowing of the ulna and radial deviated right hand (club hand) and associated single umbilical artery. The finding of the radial ray syndrome shown on 2D ultrasound was further confirmed on 3D ultrasound. Based on the finding of complete absence of radius this was diagnosed as unilateral type IV radial ray syndrome.

Figure 1: (A) - Gray scale ultrasound showing absent right radius bone.

*Professor, **Assistant Professor, ***Junior Resident
Department of Radiodiagnosis, SMS Medical College, Jaipur.
Corresponding author-
Dr Pankaj Nitharwal, Assistant Professor, Department of Radiodiagnosis, SMS Medical College, Jaipur.
Email: pankaj6468@gmail.com
Mobile: +91-8447445938

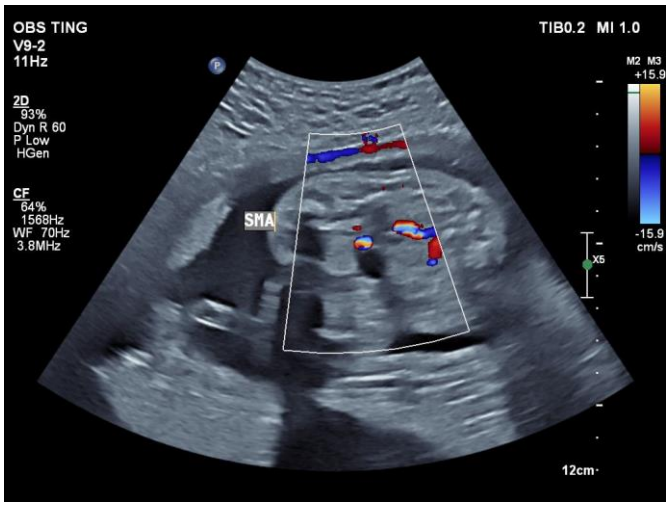

(B) - Colour doppler ultrasound showing single umbilical artery

Figure 2: (A) Gray scale ultrasound showing radial deviation of right hand.

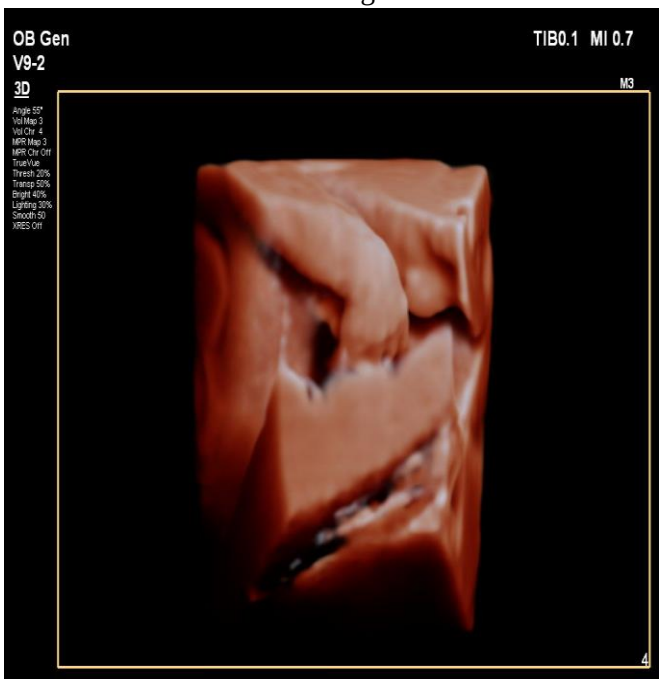

(B) - 3D ultrasound image showing radial deviation of right hand (club hand)

CONCLUSION

Radial ray anomaly in combination with club hand is a rare and an interesting phenomenon which can be diagnosed in the prenatal period. Fetus discovered to have abnormal limbs/hands should be referred to a center for counseling to parents and family and ensure proper management and rehabilitation[4,5].

REFERENCES

1. Niswander L, Jeffrey S, Martin GR, Tickle C. A positive feedback loop coordinates growth and patterning in the vertebrate limb. Nature. 1994 Oct 13;371(6498):609-12.
2. James MA, McCarroll Jr HR, Manske PR. The spectrum of radial longitudinal deficiency: a modified classification. The Journal of hand surgery. 1999 Nov 1;24(6):1145-55.
3. ArKennelly MM, Moran P. A clinical algorithm of prenatal diagnosis of Radial Ray Defects with two and three dimensional ultrasound. Prenatal Diagnosis. 2007 Aug;27(8):730-7
4. Yang PY, Yeh GP, Hsieh CT. Prenatal diagnosis of radial ray defects by ultrasound: a report of 6 cases. Taiwanese Journal of Obstetrics and Gynecology. 2018 Aug 1;57(4):598-600.
5. Arryu JK, Cho JY, Choi JS. Prenatal sonographic diagnosis of focal musculoskeletal anomalies. Korean Journal of Radiology. 2003 Dec 1;4(4):243-51.